

# Globe avulsion due to impact by motor cycle gear shift

*by* Habibah Muhiddin

---

FILE	URNAL_CASE_REPORTS_AND_IMAGES_IN_OPTHALMOLOGY_VOL._2,_ _2019.PDF (793.28K)	WORD COUNT	2280
TIME SUBMITTED	12-FEB-2021 09:39AM (UTC+0700)	CHARACTER COUNT	11951
SUBMISSION ID	1507627024		

# Globe avulsion due to impact by motor cycle gear shift

Dian Furqani Ibrahim, Halimah Pagarra,  
Habibah S Muhiddin, Yunita

## ABSTRACT

**Introduction:** Motor cycle accident is one of the leading cause of eye injury in Indonesia and vision loss are possible outcomes due to its high impact. Some eye injuries that can occur following motor cycle accident are eyelid lacerations, corneal injuries, iris injuries, hyphema, eye socket injuries, retinal injuries, optic nerve injuries or even worse such as eye globe avulsion. **Case Report:** This is a comprehensive case report of a 19-year-old male presented with a globe avulsion after a motor vehicle trauma. The left globe was luxated out of the orbit. The superior and inferior lids were lacerated full thickness. There was corneal haze and no eye movement. **Computed tomography (CT) scan** showed blow out fracture of the left inferior orbital wall and hematosinus. There was no sign of intracranial trauma as well as other facial fractures and soft tissue injuries. The patient was enucleated after further assessment of the globe. The final follow up showed excellent cosmetic result after prosthetic fitting. **Conclusion:** Traumatic globe avulsion is a rare complication of trauma. In developing country like Indonesia, safety measures while using a motor vehicle is not taken seriously and laws regarding traffic safety and regulations are not enforced to the fullest extent. Low education and minimal safety promotion increase the possibility of ocular injuries.

Dian Furqani Ibrahim<sup>1</sup>, Halimah Pagarra<sup>1</sup>, Habibah S Muhiddin<sup>1</sup>, Yunita<sup>1</sup>

**Affiliation:** <sup>1</sup>Department of Ophthalmology, Faculty of Medicine, Hasanuddin University, Wahidin Sudirohusodo Hospital, Makassar, Indonesia.

**Corresponding Author:** Halimah Pagarra, Department of Ophthalmology, Faculty of Medicine, Hasanuddin University, Wahidin Sudirohusodo Hospital, Makassar, Indonesia; Email: halimah\_pa@yahoo.com

16

Received: 08 February 2019  
Accepted: 12 April 2019  
Published: 24 July 2019

**Keywords:** Enucleation, Eye globe avulsion, Motor-cycle accident

## How to cite this article

Ibrahim DF, Pagarra H, Muhiddin HS, Yunita. Globe avulsion due to impact by motor cycle gear shift. J Case Rep Images Ophthalmol 2019;2:100010Z17DI2018.

Article ID: 100010Z17DI2018

\*\*\*\*\*

doi: 10.5348/100010Z17DI2019CR

## INTRODUCTION

Eye globe avulsion is a result of extreme trauma. Although the spectrum of eye globe injuries is wide, however total avulsion of the eye globe is rare [1]. Eye globe avulsions are classified as incomplete and complete [2, 3]. In complete eye globe avulsion there is a disruption of the extraocular muscles and optic nerve resulting in total luxation of the ocular bulb, whereas incomplete avulsion only the optic nerve is damaged severely [2, 3]. We report a case of traumatic avulsion associated with motor vehicle accident.

13

## CASE REPORT

A 19-year-old male presented to the emergency room. The patient met with a motor cycle accident seven days prior to admission. He was using a helmet without a face cover. He was found with the gear shift of the motorcycle which is present in the foot area, embedded below the eye into the socket and he had to be pulled away from it. At the emergency room, he was conscious with a GCS of 15/15. On physical examination the left eye was positioned outside the eyelid fissure, hanging by an array of tissues that seemed to be superior and inferior oblique muscles as well as orbital fat (Figure 1). The inferior palpebra

5

was lacerated full thickness and hanging by the temporal canthus (Figure 2).

Clinically, the patient also had a blowout fracture and hematosinus in the left maxillary sinus (Figure 3). CT scan images also showed protrusion of the left globe suggestive of avulsion of the optic nerve (Figure 3). Intracranial structures were normal as well as the right eye that had 20/20 vision and no sign of trauma. The patient was hospitalized and intravenous antibiotic and corticosteroid were continued.

The patient underwent surgery. Exploration was done under general anesthesia and then enucleation was done due to the improbability of repositioning the eyeball and no possibility of recovering visual function. Before the procedure, further examination was done to evaluate the extent of the trauma. It was found that the rectus muscle was released entirely from the globe except for the superior and inferior oblique muscles. The optic nerve was avulsed at 20 mm posterior to the globe (Figure 4). There was a full thickness wound horizontally in the posterior portion of the globe lateral to the optic nerve which causes the globe to become hypotonous.

Both of the superior and inferior lid was lacerated full thickness. The superior lid was lacerated 10 mm from the lateral canthus. The inferior lid was lacerated full thickness starting at 5 mm from the nasal canthus to the temporal side with a width of 25 mm making the inferior lid avulsed and hanging from the temporal canthus. Both of the superior lid and inferior lid was sutured back to its anatomical position starting at the grey line. The conjunctival part of the palpebra was then sutured, followed by the orbicularis oculi muscles and ending it with a subcuticular suture of the skin for better esthetics. The final follow up showed excellent cosmetic result after prosthetic fitting (Figure 5).

## DISCUSSION

Fifty-five million eye trauma cases happen every year around the world. In Indonesia, eye trauma is the 6th most common trauma [4]. Eye trauma is classified by Birmingham eye trauma terminology (BETTS) and generally classified as open and closed eye globe injury [5]. In this case, the patient has an open eye globe injury due to a high impact collision to a foot gear shift, causing a rupture in the ocular wall, laceration of the lower lid, blow out fracture and avulsion of the eye globe. Avulsion of the eye globe has its own classification; complete avulsion in which there is disruption of the extraocular muscles and optic nerve resulting in total luxation of the ocular bulb, whereas in incomplete avulsion only the optic nerve is damaged severely [2, 3]. Eye globe avulsion can be a rare finding and it is usually caused by severe trauma to the head, face and orbit [4]. The mechanism of trauma that may cause eye globe avulsion are (a) elongated object enters the medial orbit, causing the globe to propel forward, (b) a wedge shape object enters the eye globe

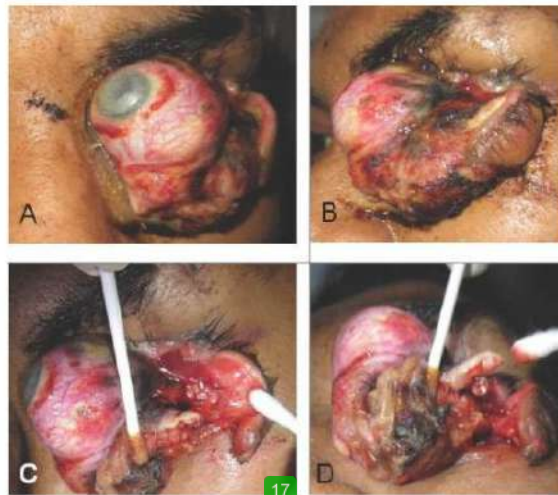


Figure 1(A-D): Pre-operative photograph of the patient showing the right eye that is salvaged and avulsion of the left eye without other visible damage to the surrounding tissue in the facial area other than excoriation of the skin.

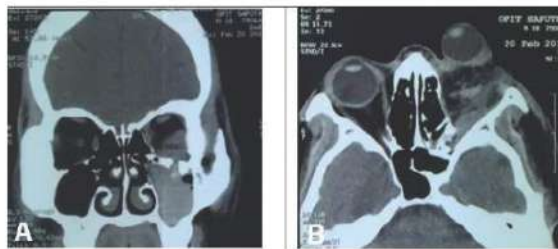

Figure 2: Photograph of the patient showing (A) anterior, and (B) inferior view of patient with orbital avulsion.

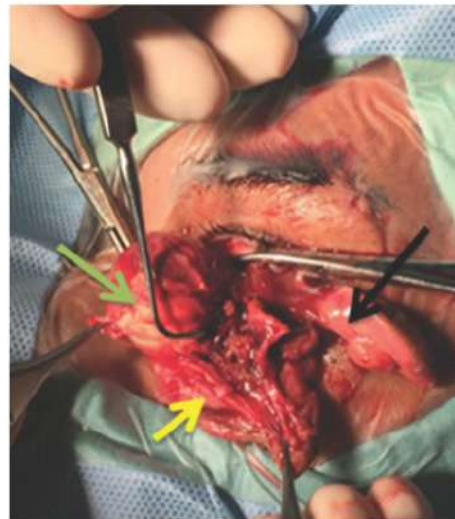


Figure 3: Photograph during surgery. Supra-cilia shown with blue arrow. Full thickness laceration of the superior lid (black arrows). Full thickness laceration of the inferior lid (yellow arrow). The globe moved nasally (green arrow).

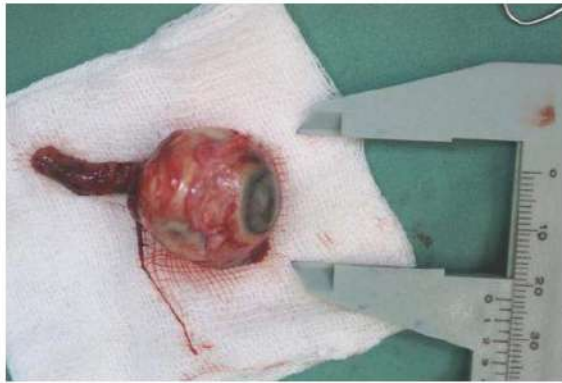

Figure 4: The enucleated eye measure 18×18×20 mm with avulsion of the optic nerve at 20 mm posterior of the globe.

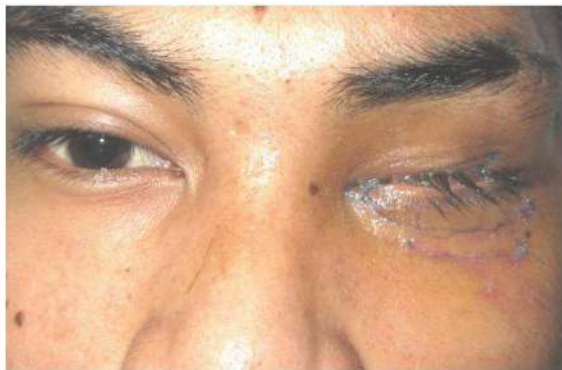

Figure 5: Post-operative results of the patient after enucleation. The subcuticular suture made a better esthetic appearance of the previous rigged laceration.

forward, displaing the eye globe anteriorly, (c) a sharp object penetrate and directly transect the optic nerve [6]. Several cases have been reported with various mechanism of trauma such as motor vehicle accident, bear attack, domestic violence, sport injuries, or trauma due to self-gauging with a finger by patient with drug abuse [2, 7, 8].

The patient was riding a motorcycle when he collided with another motorcycle from the opposite direction. The patient was propelled forward and landed with his face towards the foot gear shift of the opposing motorcycle. He was wearing a helmet, however it was without face cover. This is probably the reason behind the salvaging other structures of the face including bone and soft tissues surrounding the avulsed globe. The foot gear shift has a blunt edge to it, however with a high force, it can serve as a wedge that displace the eye globe anteriorly causing globe avulsion as well as rigged edges laceration at the lower and upper lid and blow out fracture.

With high impact, a blunt object enters the orbit with high force and damages the ocular muscles. The rupture may happen due to direct impact anterior to the annulus of Zinn, hence all four rectus muscles were damaged.

The superior oblique muscle was untouched due to its superior position in anatomy compared to the rectus muscles. Additional damage may also have occurred when the patient was pulled away from the foot gear shift. The inferior oblique muscle was unharmed due to the entrance of the object that was lower than its anatomical position.

The fracture occur in the maxillary bone (inferior wall of the orbit) and combined with the bleeding in the orbital area, the blood entered the maxillary sinus during the appearance of hematosinus in the CT scan. The orbit is the bony cavity that contains the globe, extraocular muscles, nerves, fat and blood vessels [9]. This cavity consist of four walls; the roof, the floor, the lateral and medial wall, the weakest point being the lamina papyracea located in the posteromedial portion of the maxillary bone [9].

## CONCLUSION

Globe avulsion is one of the complication of head trauma and is a rare ocular trauma presentation. In Indonesia, safety measures on the road is not taken seriously and laws regarding traffic safety and regulations are not enforced to the fullest extent. Low education and minimal safety promotion increase the possibility of ocular injuries. With this case report we hope to bring awareness to motorcycle users to always be safe and use protective helmets with aadequate protection to the face to prevent such injuries.

## REFERENCES

1. Razmjua H, Masjedi M. Traumatic bilateral globe avulsion (case report). *J Res Med Sci* 2009;14(4): 259–60.
2. Tabatabaie SZ, Rajabi MT, Khakbaz M, Malihi M. Traumatic avulsion of the globe: Report of a rare case and brief review of literature. *Iran J Ophthalmol* 2008;20(2):46–9.
3. Bajaj MS, Kedar S, Sethi A, Gupta V. Traumatic globe luxation with optic nerve transection. *Orbit* 2000;19(3):165–70.
4. Banta JT. *Ocular Trauma*. Philadelphia: Elsevier Saunders; 2007.
5. Kuhn F. *Ocular Traumatology*. Berlin: Springer; 2008.
6. Morris WR, Osborn FD, Fleming JC. Traumatic evulsion of the globe. *Ophthalmic Plast Reconstr Surg* 2002;18(4):261–7.
7. Roki N, Roka YB, Acharya R. Traumatic avulsion and bilateral eye loss: Report of two cases. *Nepal J Ophthalmol* 2013;5(2):272–4.
8. Norazah AR1, Akmal HZ, Hashima H, Vasantha T, Samsudin A. Globe avulsion secondary to maxillofacial trauma. *Med J Malaysia* 2011;66(4):359–60.
9. Foster JA, Carter KD, Durairaj VD, Kavanagh MC, Korn BS, Nelson CC, Hartstein ME. *Orbital Anatomy*. In: *Orbit, Eyelids and Lacrimal System*. San Francisco: American Academy of Ophthalmology; 2016. p. 24–40.

\*\*\*\*\*

**Author Contributions**

Dian furqani Ibrahim – Conception of the work, Design of the work, Acquisition of data, Analysis of data, Interpretation of data, Drafting the work, Revising the work critically for important intellectual content, Final approval of the version to be published, Agree to be accountable for all aspects of the work in ensuring that questions related to the accuracy or integrity of any part of the work are appropriately investigated and resolved

Halimah Pagarra – Conception of the work, Design of the work, Analysis of data, Interpretation of data, Revising the work critically for important intellectual content, Final approval of the version to be published, Agree to be accountable for all aspects of the work in ensuring that questions related to the accuracy or integrity of any part of the work are appropriately investigated and resolved

Habibah S Muhiddin – Conception of the work, Analysis of data, Interpretation of data, Revising the work critically for important intellectual content, Final approval of the version to be published, Agree to be accountable for all aspects of the work in ensuring that questions related to the accuracy or integrity of any part of the work are appropriately investigated and resolved

Yunita – Conception of the work, Analysis of data, Interpretation of data, Revising the work critically for important intellectual content, Final approval of the version to be published, Agree to be accountable for all

aspects of the work in ensuring that questions related to the accuracy or integrity of any part of the work are appropriately investigated and resolved

**Guarantor of Submission**

The corresponding author is the guarantor of submission.

**Source of Support**

None.

**Consent Statement**

Written informed consent was obtained from the patient for publication of this article.

**Conflict of Interest**

Authors declare no conflict of interest.

**Data Availability**

All relevant data are within the paper and its Supporting Information files.

**Copyright**

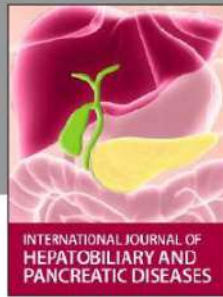
© 2019 Dian Furqani Ibrahim et al. This article is distributed under the terms of Creative Commons Attribution License which permits unrestricted use, distribution and reproduction in any medium provided the original author(s) and original publisher are properly credited. Please see the copyright policy on the journal website for more information.

Access full text article on other devices

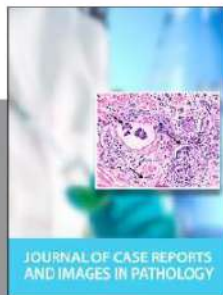
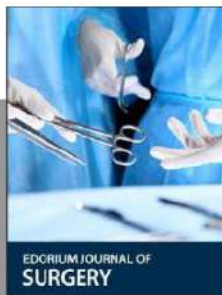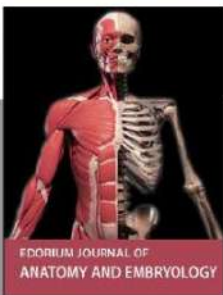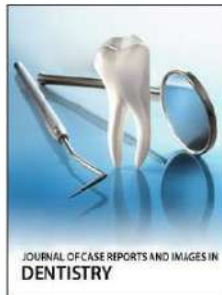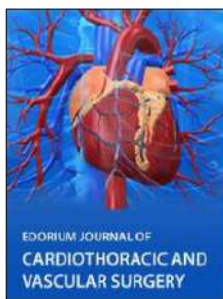


Access PDF of article on other devices





**Submit your manuscripts at**  
[www.edoriumjournals.com](http://www.edoriumjournals.com)



# Globe avulsion due to impact by motor cycle gear shift

## ORIGINALITY REPORT

% **18**  
SIMILARITY INDEX

% **12**  
INTERNET SOURCES

% **14**  
PUBLICATIONS

% **3**  
STUDENT PAPERS

## PRIMARY SOURCES

**1** [irjo.org](http://irjo.org) Internet Source % **3**

**2** [e-mjm.org](http://e-mjm.org) Internet Source % **2**

**3** Smith and Nesi's Ophthalmic Plastic and Reconstructive Surgery, 2012. Publication % **1**

**4** [link.springer.com](http://link.springer.com) Internet Source % **1**

**5** Dorsaf Touil, Rahma Bouhouch, Raoua Belkacem Chebil, Lamia Oualha, Nabih Douki. "Gingival Bleeding in a Child with Fanconi Anemia: A Case Report and Literature Review", Case Reports in Dentistry, 2020 Publication % **1**

**6** Seema Meena, Vaishali Rakheja, Sulabh Sahu, Priyanka Rathore. "Traumatic avulsion of the globe with optic nerve transection: an unusual presentation", BMJ Case Reports, 2020 Publication % **1**

7	Antonia Taiane Lopes de Moraes, Martha Caroline Auzier Quaresma, Thais Freitas Silva, Naama Waléria Alves Sousa et al. "Traumatic enucleation of the left globe after a road traffic accident – A case report of an uncommon occurrence in maxillofacial trauma", International Journal of Surgery Case Reports, 2020 Publication	% 1
8	issuu.com Internet Source	% 1
9	"Management of Open Globe Injuries", Springer Science and Business Media LLC, 2018 Publication	% 1
10	journals.plos.org Internet Source	% 1
11	Sara T., Jeffrey Goldberg. "Chapter 13 Stem Cells in Ophthalmology", IntechOpen, 2012 Publication	% 1
12	journalmc.org Internet Source	% 1
13	www.japi.org Internet Source	% 1
14	www.nepjoph.org.np Internet Source	% 1
15	KELAHMETOĞLU, Osman, ŞİMŞEK, Tekin,	

BEDEN, Ümit, OĞUZHAN AYDOĞDU, İlhami and CÖMERT HAMZAOĞLU, Ebru. "Rarely seen complication of motor vehicle accidents: Bilateral globe avulsion", Ulusal Travma ve Acil Cerrahi Derneği, 2015.

Publication

% 1

16

[www.frontiersin.org](http://www.frontiersin.org)

Internet Source

<% 1

17

David D. Limbrick. "Traumatic enucleation with avulsion of the ophthalmic artery resulting in aneurysm-like subarachnoid hemorrhage", Journal of Neurosurgery, 04/17/2009

Publication

<% 1

18

de Santana Santos, Thiago, Andr  Vajgel, Cyntia Ferreira Ribeiro, Jos  Ricardo de Santana J nior, and Ewerton Santos Andrade Filho. "Avulsion of Globe Following Maxillofacial Trauma :", Journal of Craniofacial Surgery, 2012.

Publication

<% 1

19

[biomedres.us](http://biomedres.us)

Internet Source

<% 1

EXCLUDE QUOTES ON

EXCLUDE ON

BIBLIOGRAPHY

EXCLUDE MATCHES

< 5 WORDS

